

See discussions, stats, and author profiles for this publication at: <https://www.researchgate.net/publication/303443701>

Surgical Management of Epiretinal Membrane

Chapter · February 2016

DOI: 10.5772/60513

CITATIONS

0

READS

562

4 authors:



Miltiadis K Tsimbaris
University of Crete

277 PUBLICATIONS 29,445 CITATIONS

[SEE PROFILE](#)



Chrysanthi Tsika
University of Crete

29 PUBLICATIONS 139 CITATIONS

[SEE PROFILE](#)



George Kontadakis
University of Crete

96 PUBLICATIONS 759 CITATIONS

[SEE PROFILE](#)



Athanassios Giarmoukakis
University of Crete

35 PUBLICATIONS 399 CITATIONS

[SEE PROFILE](#)

Some of the authors of this publication are also working on these related projects:



A new method, based on eye movement analysis when reading, to evaluate the effectiveness of therapeutic intervention in VEGF-related maculopathy [View project](#)



Binocularity performance to defocus-induced blur [View project](#)

Surgical Management of Epiretinal Membrane

Miltiadis K. Tsilimbaris, Chrysanthi Tsika,
George Kontadakis and Athanassios Giarmoukakis

Additional information is available at the end of the chapter

<http://dx.doi.org/10.5772/60513>

Abstract

Epiretinal membranes (ERMs) are contractile membranes that occur on the inner surface of the retina and can lead to significant visual impairment when located at the central retina. Recent advances in vitreoretinal surgery have greatly improved the safety and efficacy of microsurgical intervention at the retinal surface level. Today, vitrectomy and membrane peels are considered the treatment of choice for most patients with ERMs that create significant visual symptoms. Nevertheless, possible complications such as accelerated cataract formation, recurrence of ERM and retinal detachment may withhold the choice of surgical intervention. Additionally, in some cases, simple observation may be advised. In view of surgery, controversies regarding techniques such as those related to an internal limiting membrane peel and the use of dye still exist. In this chapter, we cover current surgical techniques for ERM removal, their expected results, possible complications, as well as a guide for possible case selection.

Keywords: Epiretinal membrane, surgical management, patient selection

1. Introduction

1.1. Classification

The disease entity of epiretinal membrane (ERM) proliferation was first described in 1865 by Iwanoff [1]. It is caused by the proliferation of avascular cellular sheets on the inner retinal surface and along the internal limiting membrane (ILM), which possesses contractile proper-

ties and as a result, leads to variable visual symptoms and visual impairments, primarily due to the mechanical distortion of the macular area. The condition's variable effect on vision is determined primarily by the severity of the retinal distortion and the location of the membrane.

ERMs can be classified according to their underlying aetiology into: a) primary or idiopathic ERMs (iERMs) [2], when no underlying causative factor or ocular pathology can be associated with the membrane formation; b) secondary ERMs, which are commonly found in association with retinal breaks and retinal detachment (RD), RD surgical repair, laser photocoagulation, retinal cryopexy, proliferative vitreoretinopathy (PVR), retinal vascular diseases, intraocular inflammation and ocular trauma [3-7]. Additionally, international literature describes rare cases of secondary ERM formation associated with type-2 neurofibromatosis [8]. In addition to the etiological classification, Gass proposed a clinical classification of ERMs based on biomicroscopical findings [9], according to which ERMs can be differentiated into three grades:

- a. Grade 0 membranes or cellophane maculopathy. Translucent membranes not associated with retinal or visual distortion.
- b. Grade 1 membranes or crinkled cellophane maculopathy. Membranes causing an irregular wrinkling of the inner retinal surface due to the contraction of the overlying membrane. Increased vascular tortuosity and perimacular vessels being pulled toward the fovea are common findings.
- c. Grade 2 membranes or macular puckers. Opaque and thick membranes that cause profound retinal distortion and tractional phenomena. Cystic macular oedema, intraretinal haemorrhages, exudates, foveal ectopia and shallow localized retinal detachment can be accompanying findings in biomicroscopy.

2. Epidemiology and pathophysiology

Idiopathic membranes and membranes associated with RD or retinal tears, as well as their management, are the most prevalent clinical phenotypes of ERM proliferation [10]. The prevalence of iERM in the general population is estimated to be approximately 6 to 7% [11], with the disease's prevalence increasing significantly with age. Specifically, according to epidemiologic studies, the prevalence of ERM formation is increasing from 2% under the age of 60 years to 12 to 20% beyond the age of 70 [2, 10], while it is bilateral in 10 to 30% of cases [11-12]. Nevertheless, lower prevalence rates have been recorded in Chinese populations [13]. Moreover, histopathological findings suggest the presence of iERMs in 1.7 to 3.5% of autopsied eyes [12-14]. Regarding secondary ERMs, the disease incidence is 4 to 8% following surgical management of rhegmatogenous RD [15-16] and 1 to 2% following precautionary treatment of peripheral retinal breaks [17].

The proposed theories regarding the underlying pathophysiology of ERM formation have been controversial; furthermore, the exact origin and type of cells that make up different types of ERMs remains an area of debate [14, 18]. Nevertheless, the general consensus is that the primary cell component in iERMs is of glial origin, more recently called laminocytes, while

secondary ERMs predominantly consist of different cell types that do not originate in the neuroretina, such as retinal pigment epithelial (RPE) cells, macrophages, myofibroblasts and fibrocytes, depending on the causative ocular pathology [19-20]. Posterior vitreous detachment (PVD), complete as well as partial, seems to play an important role in ERM pathogenesis. Specifically, it is well documented that PVD is present in up to 90% of eyes with iERMs and in fact, in all eyes with ERM formation associated with RD or retinal breaks [21]. It is therefore believed that glial cells from the neuroretina migrate through breaks in the ILM occurring during the PVD process and start to proliferate on the inner retinal surface, resulting in the formation of iERMs [18]. According to another theory, residual vitreous on the retinal surface following PVD may be related to the development of iERMs [22]. Nevertheless, iERM formation is also known to take place in eyes without PVD. In these cases, different theories have been proposed, including the migration of cells of glial origin through pre-existing ILM breaks or due to ILM thinning [23]; additionally, the vitreous traction theory proposes that astrocytic gliosis, commonly triggered by ischaemia and vitreous traction, can also occur in cases with partial or anomalous PVD (vitreoschisis), or even in the absence of PVD due to the coexistence of vitreous-retina attachment (complete or partial) with simultaneous vitreous movement, which is facilitated by the natural liquefying process of the vitreous, ultimately generating active vitreous traction and therefore, astrocytic gliosis [24]. On the other hand, the formation of secondary ERMs that develop in association with retinal breaks, RD, cryopexy and laser photocoagulation, most likely represents a form of mild PVR caused by the release of RPE cells into the vitreous cavity and their subsequent proliferation on the retinal surface [25]. In their recent work, Snead and colleagues [26], using surgically peeled membrane specimens and normal cadaver globes, determined the principal cell populations that characterize different types of ERMs, thus allowing for a clinical classification of ERMs based on their histopathological characteristics, which reflect different aetiologies. Specifically, they concluded that idiopathic ERMs are characterized by laminocytes and ILM, while the presence of laminocytes both on the ILM surface and the posterior hyaloid membrane (PHM) in cases of PVD raised the hypothesis that separation can likely occur due to the cellular activity of pre-existing laminocytes at the vitreoretinal interface. In ERMs, secondary to RD, retinal tears, PVR, trauma or intraocular inflammation, RPE cells, macrophages, lymphocytes and collagen were the primary cell components indicating that these ERMs most likely represent a tissue repair reaction. Furthermore, ERMs, secondary to PDR and vasoproliferative tumours, consisted mainly of capillaries and acellular stromal tissue, and were therefore characterized as neovascular ERMs, with hypoxia likely being the main stimulus for their formation.

In addition, recent studies implementing novel immunohistochemistry and proteomics techniques have attempted to elucidate the role of inflammatory cytokines and trophic factors in ERM development and proliferation. Basic fibroblast growth factor (bFGF) supports the survival and proliferation of glial cells and may play an important role in the ERM pathogenesis [27]. Harada et al. [28] encountered increased reactivity and expression of the bFGF in the majority of iERM and PDR-associated ERM cases studied. In accordance, similar results were reported by Chen et al. [29]. Other studies stressed the role of the nerve growth factor (NGF) and the transforming growth factors $\beta 1$ and $\beta 2$ (TGF $\beta 1$ and TGF $\beta 2$) in iERM formation and their subsequent contraction [30-31]. Authors suggested that these trophic factors possibly

induce the differentiation of glial cells into myofibroblasts, granting ERMs their contractile properties [30-31]. Increased expression of the vascular endothelial growth factor (VEGF) has also been reported in iERMs, though its exact role in the disease pathogenesis still remains unknown [29, 32-33]. Furthermore, proteins such as apolipoprotein A-1, transthyretin, α -antitrypsin, serum albumin and interleukin-6 have also been proposed to participate in the pathogenesis of the disease [27, 34].

3. Natural course and associated symptoms

ERMs tend to remain stable or to present limited progression over time, with most patients experiencing mild or no symptoms following the initial diagnosis, indicating that membrane contraction possibly occurs at an early phase after its original formation and generally stabilizes thereafter. According to the findings of the population based "Blue Mountains Eye Study", epiretinal membrane progression was encountered in 28.6% of cases, stability was noticed in 38.8% of eyes, while 25.7% of cases regressed during a five-year follow-up period [35]. Accordingly, former studies have supported the non-progressive character of the disease [36-37], since only 10 to 25% of eyes seemed to show a significant decrease in visual acuity over time, with variable rates of progression [2, 9]. In fact, previous reports suggest that less than 5% of ERM cases present visual acuity of 20/200 or worse [38-39]. Moreover, rare cases of spontaneous ERM separation from the retina with associated visual improvement have also been documented [9, 40].

ERMs are symptomatic only if the macular or peri-macular area is involved. In its mildest forms, such as in cases of cellophane maculopathy, the disease is usually asymptomatic [38-39]. Symptomatic patients usually complain of decreased visual acuity (VA), metamorphopsia or vague visual disturbances. Other less common symptoms include micropsia and monocular diplopia [38-39]. In general terms, the extent of the visual effect of the disease is determined mainly by the degree of the induced retinal distortion, the position of the membrane in association to the macula, as well as its thickness and transparency. The decrease in VA can generally be attributed to the filtering effect of the ERM that prevents light from reaching the photoreceptors, the distortion of the retinal surface, as well as the macular oedema and the associated vitreoretinal traction due to incomplete PVD, if present. The distortion of the retinal surface due to ERM contraction, which in some cases can involve the entire retinal thickness, is the primary cause for metamorphopsia, which is usually the leading and most disturbing symptom of the disease.

4. Diagnosis

The diagnosis of the disease is primarily clinical, based on fundus biomicroscopy. In its mildest form, ERM is detected only as a mild glistening light reflex from the inner retina. Fundus examination or fundus photographs with a blue filter may facilitate visualization of very thin

membranes [41]. In more advanced cases, wrinkling and/or striae of the retinal surface, as well as retinal vessel distortion may be noticed during examination. Usually, the membrane itself is invisible; nevertheless in advanced cases and particularly in cases of secondary membranes associated with retinal breaks and RD, the ERM can be seen as a grey-whitish membrane that obscures the visualization of the underlying retinal vasculature and retinal surface. Other associated biomicroscopic findings may include PVD, small intraretinal and preretinal haemorrhages, central macular oedema due to retinal vascular leakage, areas of whitening of the inner retina due to axonoplasmic stasis secondary to ischaemia, foveal ectopia due to macular traction and pseudoholes. A pseudohole is a commonly associated clinical finding and is considered to be the result of the formation of a membrane defect accompanied by the displacement of retinal tissue that occurs during the contraction of the ERM [9]. The Watzke-Allen slit beam test is a useful clinical test that can differentiate between a pseudohole and a true full-thickness macular hole [42]. In cases of a positive Watzke-Allen test, the patient will perceive a “break” in the slit beam. The test is negative in the case of a pseudohole.

Optical coherence tomography (OCT) is the most sophisticated and contemporary imaging modality in the diagnosis of ERMs. In OCT imaging, an ERM is typically demonstrated as a hyperechoic band over the retinal surface, while wrinkling of the retina is easily visualized when present. Associated clinical entities, such as vitreomacular traction, macular oedema, loss of the foveal pit and foveal ectopia due to ERM traction are also readily demonstrated using this imaging technique (Figure 1). Moreover, OCT can easily differentiate between a pseudohole and a true macular hole, and can also serve as a very useful tool in ERM preoperative planning and in postoperative follow-up.

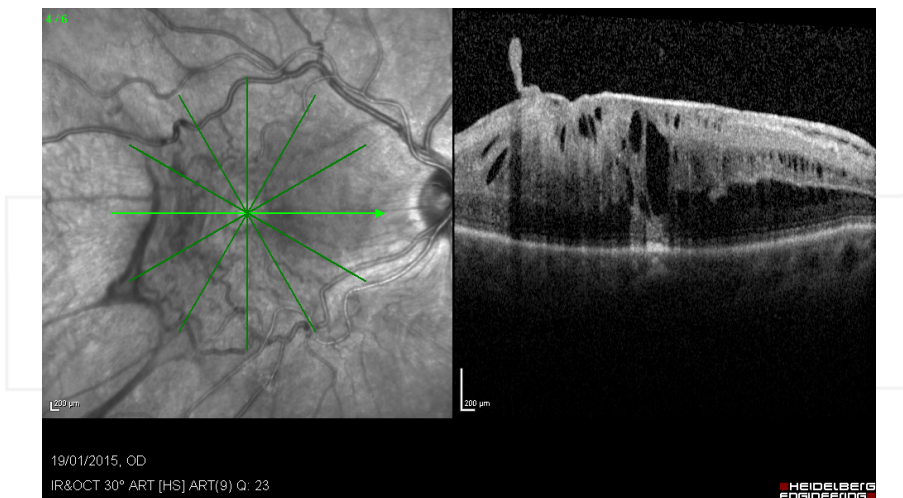


Figure 1. OCT image of an epiretinal membrane. In addition to the apparent thick membrane, the OCT scan reveals considerable macular thickening and cystoid macular oedema. Notice the prominent vascular tortuosity (left) and the obvious edge in the OCT scan of the membrane (right), which may be used for peeling initiation during surgery.

In addition, fluorescein angiography (FA) is another adjuvant diagnostic test for ERM. Despite the fact that it is usually not necessary to establish the diagnosis of an ERM, FA can be helpful in assessing the extent of vascular distortion and detect the presence of vascular leakage and macular oedema. ERM associated vascular leakage, when present, is typically irregular, asymmetric and within the area of the ERM. It is also useful to exclude other lesions that may share common clinical findings with ERMs, such as choroidal neovascularization and other vascular diseases of the retina.

5. Surgical technique and instrumentation

The rationale of the technique for removing the ERM has not changed since 1972, when Machemer introduced this procedure to vitreoretinal surgery. Machemer used a 23g bent needle to remove the epimacular membrane after 17g pars plana vitrectomy. Despite the continuous evolution and development of surgical instrumentation, the technique today remains practically the same. First, a three-port pars plana vitrectomy is performed. The ERM is then peeled off with appropriate forceps. Dyes are often used to better visualize the membrane. Sometimes, scissors are necessary for the dissection of highly-adhered membranes. Several surgeons proceed to ILM peeling as a next step in order to minimize ERM recurrence. In most cases, the operation finishes without the need for tamponade and mandatory posture.

In the following paragraphs, the steps of the procedure, as well as the necessary equipment and adjuvants are described in more detail.

5.1. Vitrectomy

A three-port pars plana vitrectomy is the first step of the procedure, although there are some reports in the literature regarding direct epiretinal membrane peeling without prior vitrectomy [43-44]. A core vitrectomy is performed, followed by posterior vitreous detachment, if this is not already present. This is done either actively with the vitreous cutter, or passively with a flute needle, starting by elevating the posterior hyaloid membrane at the level of the optic disc. Subsequently, the vitrectomy is completed with the cortex removal.

5.1.1. Microincision Vitrectomy Systems, MIVS

During the past number of years, most surgeons prefer small gauge vitrectomy systems and thus, the procedure is sutureless and atraumatic. The systems that are broadly used for the macula surgery are the 23G and the 25G, while 27G was also recently introduced [45]. The use of either system depends primarily on the surgeon's preference and they do not seem to affect postoperative outcomes [46-49]. However, the wide acceptance of the microincision systems indicates that these outnumber the 20-g system, offering shorter operating times, reduced corneal astigmatism, diminished conjunctival scarring, improved patient comfort and in some cases, earlier visual recovery [50-52]. Although this is true for most vitrectomy applications, it is especially true for macula surgery including ERM peeling.

Small gauge systems are considered to offer better postoperative comfort due to minimal surgical trauma. However, as size goes down, instruments tend to be less stiff, sometimes

rendering globe manipulation during surgery difficult. Postoperative leakage from the unsutured entry sites has been correlated to hypotony and endophthalmitis; however, the findings in the literature regarding this are not consistent [48, 50, 53-54]. Moreover, as the small cutter lumen removes smaller vitreous quantities per cut, vitreous removal is relatively slower compared to traditional vitrectomy. Recent advances in vitrectomy systems related to fluidics, cutting rates, instrument design and alloys, have succeeded in compensating for most of these drawbacks and have made microincision vitrectomy systems the preferred platform for most posterior segment surgeons. The introduction of xenon and mercury vapour lights has also helped in overcoming some early problems related to illumination. The bright illumination and low light hazard offered by these light sources, even in very small diameter systems, have helped to broaden the scope of small gauge vitrectomy.

5.1.2. Visualization systems

Extremely clear visualization of the surgical field represents one of the cornerstones of modern retinal microsurgery. Dealing with fine tissues and transparent membranes, and avoiding damage to sensitive structures, requires a very good stereoscopic view. Several systems have been introduced in surgical practice; below, the most commonly used are reviewed.

5.1.2.1. Contact lenses

Plano-concave lenses are placed directly on the cornea for posterior segment view. Their primary advantage is the high-resolution image that the surgeon obtains with their application. However, they have an important disadvantage in the form of their instability during surgery. In order to overcome this limitation, ring systems have been designed for sutureless stabilization on the cornea; at the same time, various ways have been proposed for adjusting them (e. g., on the speculum, at the cannulas etc.). Many surgeons use these lenses either separately or in combination with a non-contact system.

5.1.2.2. Non-contact systems

The first non-contact optical system for visualizing the posterior segment was presented in 1987, which was the binocular indirect ophthalmomicroscope (BIOM, Oculus, Wetzlar, Germany) [55]. It is the most frequently used wide-angle viewing system for retinal surgery. The BIOM, as all other non-contact systems, is based on indirect ophthalmoscopy, which results in an inverted image. An optical system introduced in the microscope's optical pathway is used for image re-inversion, so that the image viewed by the surgeon has normal orientation. An important feature of the BIOM is the variety of lenses that one can choose from and switch between during surgery, as it comes with a 60 deg., 90 deg. and 120 deg. refraction lens. For example, for macular surgery, a 60 deg. macula lens can be placed for the membrane peeling, while at the end of the procedure, the surgeon can switch to a 120 deg. wide field in order to check for breaks at the periphery. In first BIOM generations, the focus and the inversion of the field were manual; however, most recent BIOMs have incorporated a footswitch for focus adjustment and an automated inverter.

Other non-contact systems include the EIBOS (HS, Moeller-Wedel Optical GmbH, Wedel, Germany), the OFFISS (optic fibre free intravitreal surgery system/OFFISS; Topcon Medical

Systems, Oakland, NJ), the OptiFlex (Volk, Mentor, OH), the PWL (PWL; Ocular Instruments, Bellevue, WA) and the Resight 700 (Carl Zeiss Meditec AG, Jena, Germany). Each of them has positive (automatic inverters, adjusted illumination, automatic lens switches, etc.) and negative (adjustable in specific microscopes, unstable coaxiality, etc.) aspects. Eventually, the selection of the particular optical system will depend on the surgeon's experience, comfort and familiarity with the technique and the technology.

5.1.3. Visualization adjuncts

Vital dyes stain the faint epiretinal membranes and thus improve contrast during surgery. Their utilization has considerably facilitated macular surgery and is considered by many surgeons extremely helpful for both ERM and ILM removal [56]. Trypan Blue (TB) is the most frequently used dye and stains mainly the ERM. Brilliant Blue G (BBG) stains both the ILM and ERM and is preferred when ILM removal is also desired. Other dyes such as indocyanine green (ICG) and infracyanine green (IFCG) primarily stain the ILM and we will not discuss their use in this chapter.

The use of trypan blue for ERM staining has been well-studied and is considered an excellent, non-toxic approach for visualizing the membrane [57-59]. It is usually injected under air in order to avoid lens capsule staining; this will hinder the continuation of the operation due to the deprivation of the view of the posterior segment. Alternatively, heavy TB can be used, which does not demand an air-fluid exchange [60]. The TB is left for one- to three-minutes and is then washed away. The epiretinal membrane and other proliferative tissue are stained and their edges show against the unstained background.

Brilliant Blue G mostly stains the ILM, but the ERM is also stained to some degree [61]. It is preferred when dual staining is necessary, for simultaneous removal of ERM and ILM [62]. It is also injected under air and washed away after a few minutes. It is generally reported to be safe although some concerns about retinal toxicity have been raised [59, 63-64].

Another substance that is quite effective in visualizing ERMs is triamcinolone (TA). TA is not a dye; it forms crystals that are deposited through loosely organized collagen matrices, making visible the vitreous body, but also ERMs and the ILM [65].

5.1.4. Forceps and scissors

Fine instruments are imperative for handling fine structures such as the epiretinal membranes and the ILM to lessen possible damage to the underlying retinal tissue. Instrument sizes follow the trend of minimizing the size of the vitrectomy ports. Nowadays, forceps, scrapers, scissors and other adjuncts exist in compatibility with 20g, 23g, 25g and 27g PPV systems.

End-grasping forceps are the most commonly used instruments for ERM peeling. Klaus Eckhardt developed the first fine end-grasping forceps in the 90s; these proved to be very effective and are still preferred today. Later, Charles developed conformal forceps, meaning that they have the same radius of curvature as the retina and avoid grasping of the retinal surface by grasping the nerve fibre layer (NFL) during the procedure. Rarely, in high adherence situations, scissors can be used. Horizontal scissors are preferred because of their safer profile compared to vertical scissors. They can be inserted into the potential space between the

membrane and the retina, with both blades more efficiently delaminating the ERM from the subjacent tissue.

When the edge of the membrane is not easily grasped by forceps, a Tano diamond dusted membrane scraper (DDMS) can be used. This tool is coated with inert diamond dust that makes traction easier and offers an atraumatic alternative to finding the edge of the membrane due to its soft silicon tip. The Tano DDMS is for some surgeons an indispensable part of macular surgery. Its use is also suggested for ILM removal. However, attempting to create an edge at the ILM with this tool is strongly discouraged due to the damage it can cause to the subjacent tissue [66].

5.2. Removal technique

Once the vitrectomy is completed, the ERM is inspected for visible edges. Existing edges are visualized much better if dye has been used for ERM staining. Moreover, careful preoperative evaluation using SDOCT can be extremely helpful in this regard by providing information about the 3D configuration of the membrane and the selection of an optimum area for peel initiation. If a pre-existing edge cannot be found, it can be created using a pick or a micro-vitreoretinal (MVR) blade. The edge is then grasped with the forceps, with the one blade on the anterior surface and the other under the membrane, and a circumscribed flap is created. Then, careful and gentle dissection is started from the periphery to the centre of the membrane (outside-in technique), similar to the capsulorhexis in cataract surgery. Alternatively, the membrane is grasped centrally and peeled away from the centre, always in a circumferential pattern (inside-out technique). Some surgeons consider the inside-out technique safer, because the central retina is thicker and stronger, making it easier for the surgeon to find a tissue plane to begin with.

Since both the picking and the grasping of the membrane can cause damage to the subjacent retinal tissue (tears, bleeding, ischaemia), good visualization and controlled manoeuvres are very important at this stage. Directing the tip tangentially to the retinal surface and engaging the membrane from different directions helps to avoid fragmentation of the tissue sheet and inadvertent tearing of the retina [67].

Charles has proposed an alternative approach for minimizing tissue damage, described as “pinch peeling”. In this case, the forceps pinch the membrane without creating an “edge” and grasp it with the two blades on the surface of the membrane. Retinal contact is thus avoided and the risk of retinal damage is minimized [68].

5.2.1. ILM peeling

Very often, the ILM is peeled off together with the ERM. This can be monitored during ERM peeling by using a dye that stains both the ERM and the ILM, e. g., Membrane Blue Dual® (DORC, Japan). If this is not achieved, the ILM can be removed at a second step. ILM peeling is impossible without the creation of an opening in the inner limiting membrane. If an edge of the ILM has not been created during ERM manipulation and removal, it can be made using a pick or MVR blade, at a location away from the maculo-papillary bundle, frequently along the temporal horizontal raphe. The fine-end forceps are again used to grasp and elevate the membrane and peeling is again performed in a circular motion, extending towards the vascular

arcades. The simultaneous removal of the ILM is imperative for some surgeons, but it is not yet clear whether it affects recurrence rates [69-70] or retinal function [71-73].

5.3. Conclusion of surgery

Following ERM removal, inspection of the peripheral retina follows; if this shows no iatrogenic damage, surgery is completed by trocar removal and sclerotomy closure. If iatrogenic damage is present, breaks in the periphery without subretinal fluid accumulation can be treated by laser retinopexy or cryoretinopexy. The presence of significant amounts of subretinal fluid necessitates internal drainage, retinopexy and gas tamponade.

Although scleral ports in small gauge vitrectomy are designed so that no sutures are necessary, careful inspection of the water tightness of the ports at the conclusion of surgery is mandatory in order to avoid early postoperative hypotony. Gentle massage of the site of scleral incision after trocar removal can improve a relatively leaky incision. Occasionally, the insertion of a small suture may be necessary for a leaky scleral incision.

6. Results and prognosis

6.1. Functional results

In general, visual acuity seems to improve following ERM surgery. More than 50% of patients gain 2 or more logMAR lines and less than 10% end up with lower postoperative VA [74-76]. Preoperative vision is usually 20/63 or worse, but cases with good visual acuity have been reported to benefit from surgery, too [77]. Improvement in vision usually occurs in the first two to three months, but complete recovery may require six to 12 months following surgery. Additionally, cataract extraction is very likely to be needed shortly after ERM peeling, as nuclear sclerosis accelerates after vitrectomy [75, 77-79].

Overall, visual prognosis depends on preoperative vision, the duration of symptoms and the preoperative anatomical status of the fovea and retinal layers [74, 80]. Postoperative BCVA is better in patients with good preoperative VA, but the gain in letters seem to be greater for patients with poorer preoperative VA. This means that patients with low preoperative visual acuity do not enjoy complete recovery after macular membrane removal. Limited restoration of the VA in these patients can be due to chronic traction, which results in permanent retinal vascular incompetence. Subsequent retinal vascular leakage and persistent cystoid macular oedema restrict the restoration of macular function and anatomy.

Metamorphopsia, one of the main reasons for patients deciding to undergo surgery, has not been investigated in a methodical and quantified manner. In the few studies that have studied metamorphopsia, it appears to improve after surgery and can happen as early as the first postoperative month [81-82]. Its preoperative existence affects postoperative visual outcomes, but the duration of preoperative symptoms do not affect the postoperative visual acuity three months after surgery [81].

6.2. Anatomical outcome

Postoperative reduction of the central macular thickness (CMT) has been a consistent finding in most studies [75, 83]. Figure 2 shows the anatomic restoration of the fovea (b) and following the removal of the epimacular membrane (a) in one of our cases, six months postoperatively. Visual recovery, however, is not always correlated with the decrease of retinal thickness. Recent studies have correlated other preoperative and postoperative anatomical features with visual outcomes. OCT represents an invaluable tool for the assessment of these features, primarily by using high definition techniques. Ellipsoid zone (IS/OS) integrity, photoreceptor outer segment (PROS) length and external limiting membrane (ELM) integrity represent some of the anatomical characteristics that appear to play an important role in functional prognosis. Significant changes in ellipsoid integrity (IS/OS) have been correlated with visual outcomes, while postoperative elongation of the PROS have been described in successful cases [84].

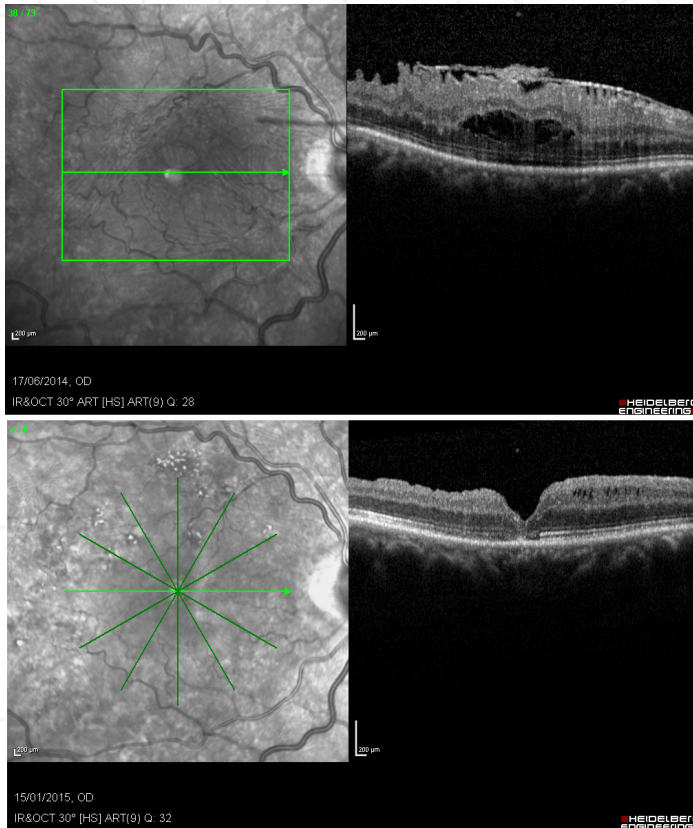


Figure 2. Anatomical restoration after ERM peeling; a) preoperative image of contracted ERM with retinal thickening and cystoid macular oedema; b) six months after surgery the foveal anatomy has greatly improved. Small intraretinal cysts can still be seen along with some changes in the outer retinal layers.

On the other hand, although postoperative visual field loss is known to occur in some cases following ERM surgery, its correlation with anatomical changes in the OCT has not been confirmed by the literature. The effect of surgery on the nerve fibre layer (NFL) and the ganglion cell layer (GCL) are under intense investigation, especially with “*en face*” OCT and other sophisticated techniques. However, the results on whether there is loss of neuronal or glial tissue remain ambiguous, as do reasons for the late deformation of the central retina, often observed following ERM surgery. Based on modern retinal imaging modalities, it is believed that retinal reconstruction continues for months after ERM peeling [85-86].

6.3. Prognosis of different ERM subtypes

Secondary epiretinal membranes have worse prognosis than idiopathic membranes [69]. Limited visual recovery, as well as higher recurrence rates, is reported. Diabetic membranes are difficult to manage, as they are accompanied by severe retinal damage that can lead to serious complications including haemorrhage, detachment and re-proliferation of the connective tissue [87]. Postoperative ERMs (including ERMs developed after vitrectomy for retinal detachment, but also after laser or cryo-retinopexy) have limited visual recovery, especially when the macula is detached [88]. Finally, inflammatory membranes illustrate variable results, depending mostly on the effect of the subjacent inflammation on the retinal function [89].

7. Complications

Epiretinal membrane removal is generally a safe procedure. Intraoperative complications involve retinal breaks, retinal haemorrhage, retinal whitening and retinal surface damage. Postoperative complications include cataract formation, rhegmatogenous retinal detachment (RRD), cystoid macular oedema, endophthalmitis and the recurrence of fibrotic tissue.

A common intraoperative complication is the creation of iatrogenic retinal breaks. These occur during vitrectomy; thus, careful examination of the periphery with indentation at the conclusion of surgery is crucial for their early/prompt diagnosis. Their treatment is straightforward, that is, through the application of intraoperative laser retinopexy or cryopexy. However, a break can also occur at the posterior pole (due to pinching or during the dissection of a high-adherent membrane) and in this case, laser treatment may be hazardous to the fovea and should be performed with caution.

Haemorrhage at the site of pinching or grasping or at the area where the membrane detaches from a retinal vessel is also common. In this case, recovery is usually short and uneventful. More extensive bleeding may occur less often when a vessel is damaged during the dissection and can be controlled by increasing intraocular pressure or intraoperative cautery.

Retinal whitening is the result of ischaemia that usually resolves intraoperatively; nevertheless, sometimes it may persist for an extended period of time. Membrane manipulation can also cause surface tissue damage, which may or may not be symptomatic. Symptoms involve primarily visual field defects and one should differentiate if these are due to tissue deficits or

ischaemia. In the first case, direct damage may be the result of pinching or gripping of the membrane; additionally, indirect damage to the inner retina can occur if ILM peeling had been part of the surgical procedure.

The most frequent postoperative complication of ERM surgery is the progression of nuclear sclerosis of the crystalline lens. Most often, visual acuity improves during the first six to nine months, but then slowly decreases as the cataract develops. The majority of phakic patients undergo cataract extraction within two years in order to maximize the benefits of the initial operation. For this reason, some surgeons prefer a combined operation of phacoemulsification, ERM peeling and IOL implantation [74-76, 90].

Rhegmatogenous retinal detachment is another important postoperative event. The cause in this case is usually a peripheral break caused by traction or incarceration of vitreous in the sclerotomies and demands surgical treatment.

Recurrence of ERMs may be seen in up to 5% of eyes with idiopathic membranes. Younger individuals, patients with a prior history of retinal detachment and patients with a prior history of uveitis tend to have a higher recurrence rate, which in some studies have been up to 12% [71]. Remarkably, recurrence is reported to be higher by many studies when ILM is left intact [69, 91].

Endophthalmitis is quite rare after standard 20g vitrectomy (0.02 to 0.14%) [92]. For transconjunctival sutureless vitrectomy (TSV) and especially when using the 25g system, higher rates have been reported (0.04 to 1.55%) [92]. Nevertheless, this finding has not been conclusively confirmed in the literature; thus, the question regarding the increased risk of infection after TSV is yet to be clarified [93-97].

8. Surgery vs. observation

Despite the favourable results of surgery for the treatment of ERM, debate remains regarding a preferable treatment strategy. Decision for surgery and selection of the proper method depends on the surgeon's preference and on the patients' characteristics. Nevertheless, it is highly significant to perform meticulous patient selection for each method in order to achieve better outcomes with regard to patients' overall visual ability and quality of life.

As discussed above, interventional studies indicate that early surgical removal can relieve disturbing symptoms and stabilize vision, which may worsen later [74-77, 81-82]. This is in contrast with the fact that ERMs do not always progress and may be stable during follow-up without any intervention [35, 98]. Moreover, there are possible side effects to surgery and the improvement in visual acuity is greater in patients with preoperative lower visual acuity.

In the paragraphs that follow, we will attempt to review data from the literature concerning surgery timing and patient selection.

Epidemiological population-based studies suggest that a large percentage of cases diagnosed with ERM may remain stable during follow-up. These studies agree that the disease is non-

progressive in a significant percentage of cases and also that regression may be observed without any intervention. In the Blue Mountains eye study, 28.6% of cases experienced progression, 38.8% of eyes remained stable and 25.7% of cases regressed in a five-year follow-up period [35]. In a prospective cohort study of 1932 patients undergoing cataract surgery, it was reported that 43% of patients progressed postoperatively after one month had passed during a 36-month follow-up, 32.4% of patients remained stable and 24.6% of patients regressed [98]. According to these results, similar percentages of patients with cellophane maculopathy and patients with preretinal fibrosis progressed; additionally, the regression rates in both groups were similar: 26% of cellophane reflex cases and 18% of preretinal fibrosis cases regressed spontaneously without surgical intervention. Of the 14 cases of preretinal fibrosis regression, five cases had complete regression, while the rest had partial ERM regression. In the Blue Mountains study, regression rates were similar in the cellophane macular reflex (CMR) group and in the preretinal macular fibrosis (PMF) group (25.7% and 25.8%, respectively). Regarding progression, 16.1% of participants with PMF at baseline and 32.8% of patients with CMR at baseline progressed, including 17 eyes in which CMR progressed to PMF (9.3%). There was no significant association between the ocular and systemic risk factors detected for predicting the progression of preretinal macular fibrosis during the five-year follow-up [35]. It appears that according to these prospective cohort studies, progression of ERM affected about a third of patients; furthermore, a small amount of patients regressed completely. The differences in percentages among studies can be attributed to the different criteria selected for progression and regression, as well as to the different study populations.

Based on these data, a follow-up period prior to making a decision for surgery was imposed in most cases, depending on the amount of visual disturbance upon diagnosis.

Regarding visual acuity, in the Blue Mountains study, the authors demonstrated that the level of mean visual acuity was only slightly affected by incident preretinal macular fibrosis and was unaffected by incident cellophane macular reflex. The average reduction of visual acuity after five years in the worst eyes was 5.7 letters (CI, 5.3 to 6.1) in subjects without incident epiretinal membranes, 7.4 letters (CI, 4.7 to 10.1) in eyes with incident preretinal macular fibrosis and 2.8 letters (CI, 1.6 to 4.0) in eyes with incident cellophane macular reflex. Corresponding mean differences in visual acuity between the baseline and a five-year examination were not statistically significant [35]. Thus, surgery was not promptly needed with regard to visual acuity, since the progression of vision loss, if any, was very slow. When surgery is undertaken in cases with significantly impaired visual acuity, it provides improvement more frequently and to a greater extent than in eyes with better preoperative visual acuity [79].

On the other hand, eyes with lower preoperative visual acuity tend to have lower final visual acuity, whereas the final visual prognosis is better for eyes with better preoperative visual acuity [79, 99]. Studies using spectral domain optical coherence tomography have shown that visual disturbance induced by ERM is associated with intraretinal changes, including the

disruption of photoreceptor integrity. These findings suggest that the damage resulting from ERMs is partially irreversible, regardless of surgical management. Consequently, from this point of view, an early intervention prior to the induction of permanent damage seems more rational.

In order to make the decision for undergoing surgery, it is important to evaluate the prognosis of surgery in each case. Preoperative evaluation with time-domain OCT (TDOCT) and spectral-domain OCT (SDOCT) has given us the ability to assess morphologic features that correspond to intraretinal tissue damage and its association with preoperative visual symptoms, and to evaluate the potential for improvement [81, 100-103]. According to clinical studies with TDOCT and SDOCT, the preoperative disruption of the photoreceptors' inner and outer segment junction (ellipsoid zone, IS/OS) is one of the main prognostic factors. Suh et al. and Falkner-Radler et al. compared TDOCT in ERM patients pre- and post- vitrectomy and found that eyes experiencing disruption of the ellipsoid zone had significantly lower postoperative best corrected visual acuity (BCVA) and lower BCVA differences when comparing pre- and post-surgery conditions, compared to those without preoperative OCT disruption [81, 100]. The latter study additionally confirmed the predictive value of ellipsoid zone integrity for postoperative functional outcomes with SDOCT [100]. Inoue et al. and Kim et al. prospectively allocated their patients based on preoperative ellipsoid zone integrity in groups of intact versus disrupted and found that the intact ellipsoid zone cohort had better final visual acuity and better improvement in visual acuity. The predictive role of the preoperative central foveal thickness, the presence of a macular pseudohole or the presence of retinal cysts was not confirmed in these studies [101-103].

Other factors that may predict visual outcome and affect decisions regarding surgery are the presence of any other macular co-morbidity such as age-related maculopathy. The length of the photoreceptor outer segment and the thickness of the inner retinal layer are also correlated with visual function, and might therefore be useful in predicting surgical outcomes [103]. Additionally, as mentioned earlier, the presence and severity of metamorphopsia has also been correlated with final visual outcomes [81-82].

9. Conclusion

Vitrectomy and membrane peeling is currently the preferred surgical treatment option for eyes with ERM. However, no consensus has been established concerning an optimal time for surgery. Early intervention may prevent the evolvement of non-reversible damage to the outer retina; however, ERM progression concerns only a small percentage of patients. Follow-up with SDOCT and clinical examination for recording visual acuity and metamorphopsia is imposed in early cases prior to decision-making. Moreover, in more advanced stages, the application of SDOCT for assessing retinal integrity and predicting postoperative outcomes is necessary in order to predict possible functional gain following surgery.

Author details

Miltiadis K. Tsilimbaris*, Chrysanthi Tsika, George Kontadakis and Athanassios Giarmoukakis

*Address all correspondence to: tsilimb@med.uoc.gr

University of Crete, Medical School, Department of Ophthalmology, Crete, Greece

References

- [1] Iwanoff A. Beiträge zur normalen und pathologischen Anatomie des Auges. Graefes Arch Clin Exp Ophthalmol. 1865; 11: 135-70.
- [2] Sidd RJ, Fine SL, Owens SL, Patz A. Idiopathic preretinal gliosis. Am J Ophthalmol. 1982;94:44-8.
- [3] Sheard RM, Sethi C, Gregor Z. Acute macular pucker. Ophthalmology. 2003; 110: 1178-1184.
- [4] Rivellesse M, George A, Sulkes D, Reichel E, Puliafito C. Optical coherence tomography after laser photocoagulation for clinically significant macular edema. Ophthalmic Surg Lasers. 2000; 31: 192-197.
- [5] Hassenstein A, Bialasiewicz AA, Richard G. Optical coherence tomography in uveitis patients. Am J Ophthalmol. 2000; 130: 669-670
- [6] Uemura A, Ideta H, Nagasaki H, Morita H, Ito k. Macular pucker after retinal detachment surgery. Ophthalmic Surg. 1992;23:116-9.
- [7] Appiah AP, Hirose T. Secondary causes of premacular fibrosis. Ophthalmology. 1989;96:389-92.
- [8] Meyers SM, Gutman FA, Kaye LD, Rothner AD. Retinal changes associated with neurofibromatosis 2. Trans Am Ophthalmol Soc 1995; 93: 245-52.
- [9] Gass JDM. Macular dysfunction caused by epiretinal membrane contraction. In: Stereoscopic Atlas of Macular Diseases: Diagnosis and Treatment. Vol. 2, 4th ed. St Louis, Mo: Mosby; 1997:938-50.
- [10] Mitchell P, Smith W, Chey T, Wang JJ, Chang A. Prevalence and associations of epiretinal membranes. The Blue Mountains Eye Study, Australia. Ophthalmology 1997; 104: 1033-40.
- [11] Pearlstone AD. The incidence of idiopathic preretinal macular gliosis. Ann Ophthalmol. 1985;17:378-80.

- [12] Roth AM, Foos RY. Surface wrinkling retinopathy in eyes enucleated at autopsy. *Trans Am Acad Ophthalmol Otolaryngol.* 1971;75(5):1047-58.
- [13] Duan XR1, Liang YB, Friedman DS, Sun LP, Wei WB, Wang JJ, Wang GL, Liu W, Tao QS, Wang NL, Wong TY. Prevalence and associations of epiretinal membranes in a rural Chinese adult population: the Handan Eye Study. *Invest Ophthalmol Vis Sci.* 2009; 50(5):2018-23.
- [14] Clarkson JG, Green WR, Massof D. A histopathologic review of 168 cases of preretinal membrane. *Am J Ophthalmol.* 1977;84(1):1-17.
- [15] Uemura A, Ideta H, Nagasaki et al. Macular pucker after retinal detachment surgery. *Ophthalmic Surg.* 1992;23:116-9.
- [16] Lobes LA Jr., Burton TC. The incidence of macular pucker after retinal detachment surgery. *Am J Ophthalmol.* 1978;85:72-7.
- [17] Michels RG, Wilkinson CP, Rice TA. *Retinal detachment.* St Louis: CV Mosby; 1990:1096-8.
- [18] Smiddy WE, Maguire AM, Green et al. Idiopathic epiretinal membranes. Ultrastructural characteristics and clinicopathologic correlation. *Ophthalmology* 1989; 96:811-821.
- [19] Yamashita H, Hori S, Masuda K. Population and proportion of component cells in preretinal membranes. *Jpn J Ophthalmol* 1986; 30:269-281.
- [20] Kampik A, Kenyon KR, Michels RG, Green WR, de la Cruz ZC. Epiretinal and vitreous membranes. Comparative study of 56 cases. *Arch Ophthalmol* 1981; 99:1445-1454.
- [21] Hirokawa H, Jalkh AE, Takahashi et al. Role of the vitreous in idiopathic preretinal macular fibrosis. *Am J Ophthalmol.* 1986;101:166-9.
- [22] Hikichi T, Takahashi M, Trempe CL, Schepens CL. Relationship between premacular cortical vitreous defects and idiopathic premacular fibrosis. *Retina.* 1995;15(5):413-6.
- [23] Heilskov TW, Massicotte SJ, Folk JC. Epiretinal macular membranes in eyes with attached posterior cortical vitreous. *Retina.* 1996;16:279-84.
- [24] Kampik A. Pathology of epiretinal membrane, idiopathic macular hole, and vitreo-macular traction syndrome. *Retina.* 2012; 32(2):194-8
- [25] Cherfan GM, Smiddy WE, Michels et al. Clinicopathologic correlation of pigmented epiretinal membranes. *Am J Ophthalmol.* 1988;106:536-45.
- [26] Snead DR, James S, Snead MP. Pathological changes in the vitreoretinal junction 1: epiretinal membrane formation. *Eye (Lond).* 2008 Oct;22(10):1310-7.

- [27] Harada C, Mitamura Y, Harada T. The role of cytokines and trophic factors in epiretinal membranes: involvement of signal transduction in glial cells. *Prog Retin Eye Res.* 2006; 25(2):149-64.
- [28] Harada T, Harada C, Mitamura Y, Akazawa C, Ohtsuka K, Ohno S, Takeuchi S, Wada K. Neurotrophic factor receptors in epiretinal membranes after human diabetic retinopathy. *Diabetes Care.* 2002 Jun;25(6):1060-5.
- [29] Chen YS, Hackett SF, Schoenfeld CL, Vinoses MA, Vinoses SA, Campochiaro PA. Localisation of vascular endothelial growth factor and its receptors to cells of vascular and avascular epiretinal membranes. *Br J Ophthalmol.* 1997;81(10):919-26.
- [30] Minchiotti S, Stampachiacchiere B, Micera A, Lambiase A, Ripandelli G, Billi B, Bonini S. Human idiopathic epiretinal membranes express NGF and NGF receptors. *Retina.* 2008; 28(4):628-37.
- [31] Iannetti L, Accorinti M, Malagola R, Bozzoni-Pantaleoni F, Da Dalt S, Nicoletti F, Gradini R, Traficante A, Campanella M, Pivetti-Pezzi P. Role of the intravitreal growth factors in the pathogenesis of idiopathic epiretinal membrane. *Invest Ophthalmol Vis Sci.* 2011; 52(8):5786-9.
- [32] Mandelcorn E, Khan Y, Javorska L, Cohen J, Howarth D, Mandelcorn M. Idiopathic epiretinal membranes: cell type, growth factor expression, and fluorescein angiographic and retinal photographic correlations. *Can J Ophthalmol.* 2003 ;38(6):457-63.
- [33] Joshi M, Agrawal S, Christoforidis JB. Inflammatory mechanisms of idiopathic epiretinal membrane formation. *Mediators Inflamm.* 2013;2013:192582.
- [34] Mandal N, Kofod M, Vorum H, Villumsen J, Eriksen J, Heegaard S, Prause JU, Ahuja S, Honoré B, la Cour M. Proteomic analysis of human vitreous associated with idiopathic epiretinal membrane. *Acta Ophthalmol.* 2013; 91(4):333-4.
- [35] Fraser-Bell S, Guzowski M, Rochtchina et al. Five-Year Cumulative Incidence and Progression of Epiretinal Membranes The Blue Mountains Eye Study. *Ophthalmology* 2003;110:34-40.
- [36] Hayashi K, Hayashi H. Influence of phacoemulsification surgery on progression of idiopathic epiretinal membrane. *Eye.* 2009; 23(4):774-9.
- [37] Charlap RS, Yagoda AD, Debbi S, Bodine SR, Walsh JB, Henkind P. Idiopathic preretinal macular gliosis: a retrospective study of 200 patients. *Ann Ophthalmol.* 1992; 24(10):381-5.
- [38] Wiznia RA. Natural history of idiopathic preretinal macular fibrosis. *Ann Ophthalmol.* 1982; 14:876-878.
- [39] Wise GN. Clinical features of idiopathic preretinal macular fibrosis. *Am J Ophthalmol.* 1975; 79:349-357.

- [40] Messner KH. Spontaneous separation of preretinal macular fibrosis. *Am J Ophthalmol.* 1977; 83:9-11.
- [41] Tadayoni R, Paques M, Massin P, Mouki-Benani S, Mikol J, Gaudric A. Dissociated optic nerve fiber layer appearance of the fundus after idiopathic epiretinal membrane removal. *Ophthalmology* 2001;108:2279-83.
- [42] Tanner V, Williamson TH. Watzke-Allen slit beam test in macular holes confirmed by optical coherence tomography. *Arch Ophthalmol.* 2000;118(8):1059-63.
- [43] Sawa M, Saito Y, Hayashi A, Kusaka S, Ohji M, Tano Y. Assessment of nuclear sclerosis after nonvitrectomizing vitreous surgery. *Am J Ophthalmol.* 2001;132(3):356-62.
- [44] Longo A, Avitabile T, Bonfiglio V, Toro MD, Russo A, Viti F, Nicolai M, Saitta A, Giovannini A, Mariotti C. Transconjunctival nonvitrectomizing vitreous surgery versus 25-gauge vitrectomy in patients with epiretinal membrane: A Prospective Randomized Study. *Retina* 2014 [In Press].
- [45] Oshima Y, Wakabayashi T, Sato T, Ohji M, Tano Y. A 27-gauge instrument system for transconjunctival sutureless microincision vitrectomy surgery. *Ophthalmology* 2010;117:93-102 e102.
- [46] El Sanharawi M, Lecuen N, Barale PO, Bonnel S, Basli E, Borderie V, Laroche L, Monin C. 25-, 23-, and 20-gauge vitrectomy in epiretinal membrane surgery: a comparative study of 553 cases. *Graefes Arch Clin Exp Ophthalmol.* 2011;249(12):1811-9.
- [47] Grosso A, Charrier L, Lovato E, Panico C, Mariotti C, Dapavo G, Chiuminatto R, Siliquini R, Gianino MM. Twenty-five-gauge vitrectomy versus 23-gauge vitrectomy in the management of macular diseases: a comparative analysis through a Health Technology Assessment model. *Int Ophthalmol.* 2014;34:217-223.
- [48] Haas A, Seidel G, Steinbrugger I, Maier R, Gasser-Steiner V, Wedrich A, Weger M. Twenty-three-gauge and 20-gauge vitrectomy in epiretinal membrane surgery. *Retina* 2010;30:112-116.
- [49] Kusahara S, Ooto S, Kimura D, Itoi K, Mukuno H, Miyamoto N, Akimoto M, Kuriyama S, Takagi H. Outcomes of 23- and 25-gauge transconjunctival sutureless vitrectomies for idiopathic macular holes. *Br J Ophthalmol.* 2008;92(9):1261-4.
- [50] Rizzo S, Genovesi-Ebert F, Murri S, Belting C, Vento A, Cresti F, Manca ML. 25-gauge, sutureless vitrectomy and standard 20-gauge pars plana vitrectomy in idiopathic epiretinal membrane surgery: a comparative pilot study. *Graefes Arch Clin Exp Ophthalmol.* 2006;244(4):472-9.
- [51] Goncu T, Gurelik G, Hasanreisoglu B. Comparison of efficacy and safety between transconjunctival 23-gauge and conventional 20-gauge vitrectomy systems in macular surgery. *Korean J Ophthalmol.* 2012;26(5):339-46.

- [52] Galway G, Drury B, Cronin BG, Bourke RD. A comparison of induced astigmatism in 20- vs 25-gauge vitrectomy procedures. *Eye* 2010;24:315-317.
- [53] Valmaggia C. Pars plana vitrectomy with 25-gauge instruments in the treatment of idiopathic epiretinal membranes. *Klin Monbl Augenheilkd*. 2007;224:292-296.
- [54] Thompson JT. Advantages and limitations of small gauge vitrectomy. *Surv Ophthalmol*. 2011;56:162-172.
- [55] Spitznas M. A binocular indirect ophthalmomicroscope (BIOM) for non-contact wide-angle vitreous surgery. *Graefes Arch Clin Exp Ophthalmol*. 1987;225:13-15.
- [56] Hernandez F, Alpizar-Alvarez N, Wu L. Chromovitrectomy: an update. *Journal of ophthalmic & vision research* 2014;9:251-259.
- [57] Kwok AK, Lai TY, Li WW, Yew DT, Wong VW. Trypan blue- and indocyanine green-assisted epiretinal membrane surgery: clinical and histopathological studies. *Eye*. 2004;18:882-888.
- [58] Feron EJ, Veckeneer M, Parys-Van Ginderdeuren R, Van Lommel A, Melles GR, Stalmans P. Trypan blue staining of epiretinal membranes in proliferative vitreoretinopathy. *Arch Ophthalmol*. 2002;120:141-144.
- [59] Creuzot-Garcher C, Acar N, Passemard M, Bidot S, Bron A, Bretillon L. Functional and structural effect of intravitreal indocyanine green, triamcinolone acetonide, trypan blue, and brilliant blue G on rat retina. *Retina*. 2010;30:1294-1301.
- [60] Lesnik Oberstein SY, Mura M, Tan SH, de Smet MD. Heavy trypan blue staining of epiretinal membranes: an alternative to infracyanine green. *Br J Ophthalmol*. 2007;91:955-957.
- [61] Totan Y, Guler E, Dervisogullari MS. Brilliant Blue G assisted epiretinal membrane surgery. *Sci Rep*. 2014;4:3956.
- [62] Shimada H, Nakashizuka H, Hattori T, Mori R, Mizutani Y, Yuzawa M. Double staining with brilliant blue G and double peeling for epiretinal membranes. *Ophthalmology* 2009;116:1370-1376.
- [63] Penha FM, Pons M, Costa Ede et al. Effect of vital dyes on retinal pigmented epithelial cell viability and apoptosis: implications for chromovitrectomy. *Ophthalmologica*. 2013;230 Suppl 2:41-50.
- [64] Penha FM, Pons M, Costa EF, Barros NM, Rodrigues EB, Cardoso EB, Dib E, Maia M, Marin-Castaño ME, Farah ME. Retinal pigmented epithelial cells cytotoxicity and apoptosis through activation of the mitochondrial intrinsic pathway: role of indocyanine green, brilliant blue and implications for chromovitrectomy. *PloS one* 2013;8:e64094.

- [65] Konstantinidis L, Berguiga M, Beknazar E, Wolfensberger TJ. Anatomic and functional outcome after 23-gauge vitrectomy, peeling, and intravitreal triamcinolone for idiopathic macular epiretinal membrane. *Retina* 2009;29:1119-1127.
- [66] Kuhn F, Mester V, Berta A. The Tano Diamond Dusted Membrane Scraper: indications and contraindications. *Acta Ophthalmol Scand*. 1998;76:754-755.
- [67] Bopp, S. 2005. Is There Room for Improvement in Pucker Surgery? In: Kirshhof, B. & Wong, D. ed *Vitreo-retinal Surgery, Essentials in Ophthalmology*. Berlin Heidelberg. Springer, pp: 37-65.
- [68] Charles S. Techniques and tools for dissection of epiretinal membranes. *Graefes Arch Clin Exp Ophthalmol*. 2003;241:347-352.
- [69] Kang KT, Kim KS, Kim YC. Surgical results of idiopathic and secondary epiretinal membrane. *Int Ophthalmol*. 2014;34:1227-1232.
- [70] Oh HN, Lee JE, Kim HW, Yun IH. Clinical outcomes of double staining and additional ILM peeling during ERM surgery. *Korean J Ophthalmol*. 2013;27:256-260.
- [71] Sandali O, El Sanharawi M, Basli E, Bonnel S, Lecuen N, Barale PO, Borderie V, Laroche L, Monin C. Epiretinal membrane recurrence: incidence, characteristics, evolution, and preventive and risk factors. *Retina*. 2013;33:2032-2038.
- [72] Kwok A, Lai TY, Yuen KS. Epiretinal membrane surgery with or without internal limiting membrane peeling. *Clin Experiment Ophthalmol*. 2005;33:379-385.
- [73] Abdelkader E, Lois N. Internal limiting membrane peeling in vitreo-retinal surgery. *Surv Ophthalmol*. 2008;53:368-396.
- [74] Moisseiev E, Davidovitch Z, Kinori M, Loewenstein A, Moisseiev J, Barak A. Vitrectomy for idiopathic epiretinal membrane in elderly patients: surgical outcomes and visual prognosis. *Curr Eye Res*. 2012;37:50-54.
- [75] Lee PY, Cheng KC, Wu WC. Anatomic and functional outcome after surgical removal of idiopathic macular epiretinal membrane. *Kaohsiung J Med Sci*. 2011;27:268-275.
- [76] Chuang L-H, Wang N-K, Chen et al. Comparison of visual outcomes after epiretinal membrane surgery. *Taiwan J Ophthalmol*. 2012;2:56-59.
- [77] Thompson JT. Vitrectomy for epiretinal membranes with good visual acuity. *Trans Am Ophthalmol Soc*. 2004;102:97-103; discussion 103-105.
- [78] Lee JW, Kim IT. Outcomes of idiopathic macular epiretinal membrane removal with and without internal limiting membrane peeling: a comparative study. *Jpn J Ophthalmol*. 2010;54:129-134.
- [79] Song SJ, Kuriyan AE, Smiddy WE. Results and Prognostic Factors for Visual Improvement after Pars Plana Vitrectomy for Idiopathic Epiretinal Membrane. *Retina* 2015 [In press].

- [80] Benhamou N, Massin P, Spolaore R, Paques M, Gaudric A. Surgical management of epiretinal membrane in young patients. *Am J Ophthalmol.* 2002;133:358-364.
- [81] Falkner-Radler CI, Glittenberg C, Hagen S, Benesch T, Binder S. Spectral-domain optical coherence tomography for monitoring epiretinal membrane surgery. *Ophthalmology.* 2010;117:798-805.
- [82] Kinoshita T, Imaizumi H, Okushiba U, Miyamoto H, Ogino T, Mitamura Y. Time course of changes in metamorphopsia, visual acuity, and OCT parameters after successful epiretinal membrane surgery. *IOVS.* 2012;53:3592-3597.
- [83] Kim J, Rhee KM, Woo SJ, Yu YS, Chung H, Park KH. Long-term temporal changes of macular thickness and visual outcome after vitrectomy for idiopathic epiretinal membrane. *Am J Ophthalmol.* 2010;150:701-709.
- [84] Hashimoto Y, Saito W, Saito M, Hirooka K, Fujiya A, Yoshizawa C, Noda K, Ishida S. Retinal outer layer thickness increases after vitrectomy for epiretinal membrane, and visual improvement positively correlates with photoreceptor outer segment length. *Graefes Arch Clin Exp Ophthalmol.* 2014;252:219-226.
- [85] Pichi F, Lembo A, Morara M, Veronese C, Alkabes M, Nucci P, Ciardella AP. Early and late inner retinal changes after inner limiting membrane peeling. *Int Ophthalmol.* 2014;34:437-446.
- [86] Kumagai K, Ogino N, Furukawa M, Hangai M, Kazama S, Nishigaki S, Larson E. Retinal thickness after vitrectomy and internal limiting membrane peeling for macular hole and epiretinal membrane. *Clin Ophthalmol.* 2012;6:679-688.
- [87] Hsu YR, Yang CM, Yeh PT. Clinical and histological features of epiretinal membrane after diabetic vitrectomy. *Graefes Arch Clin Exp Ophthalmol.* 2014;252:401-410.
- [88] Martinez-Castillo V, Boixadera A, Distefano L, Zapata M, Garcia-Arumi J. Epiretinal membrane after pars plana vitrectomy for primary pseudophakic or aphakic rhegmatogenous retinal detachment: incidence and outcomes. *Retina.* 2012;32:1350-1355.
- [89] Tanawade RG, Tsierkezou L, Bindra MS, Patton NA, Jones NP. Visual Outcomes of Pars Plana Vitrectomy with Epiretinal Membrane Peel in Patients with Uveitis. *Retina.* 2014 [In Press].
- [90] Yiu G, Marra KV, Wagley S, Krishnan S, Sandhu H, Kovacs K, Kuperwaser M, Arroyo JG. Surgical outcomes after epiretinal membrane peeling combined with cataract surgery. *Br J Ophthalmol.* 2013;97:1197-1201.
- [91] Pournaras CJ, Emarah A, Petropoulos IK. Idiopathic macular epiretinal membrane surgery and ILM peeling: anatomical and functional outcomes. *Semin Ophthalmol.* 2011;26:42-46.

- [92] Dave VP, Pathengay A, Schwartz SG, Flynn HW Jr. Endophthalmitis following pars plana vitrectomy: a literature review of incidence, causative organisms, and treatment outcomes. *Clin Ophthalmol*. 2014;8:2183-2188.
- [93] Hu AY, Bourges JL, Shah SP, Gupta A, Gonzales CR, Oliver SC, Schwartz SD. Endophthalmitis after pars plana vitrectomy a 20- and 25-gauge comparison. *Ophthalmology*. 2009;116:1360-1365.
- [94] Scott IU, Flynn HW Jr, Acar N, Dev S, Shaikh S, Mitra RA, Arevalo JF, Kychenthal A, Kunselman A. Incidence of endophthalmitis after 20-gauge vs 23-gauge vs 25-gauge pars plana vitrectomy. *Graefes Arch Clin Exp Ophthalmol*. 2011;249:377-380.
- [95] Govetto A, Virgili G, Menchini F, Lanzetta P, Menchini U. A systematic review of endophthalmitis after microincisional versus 20-gauge vitrectomy. *Ophthalmology*. 2013;120:2286-2291.
- [96] Scott IU, Flynn HW Jr, Dev S, Shaikh S, Mitra RA, Arevalo JF, Kychenthal A, Acar N. Endophthalmitis after 25-gauge and 20-gauge pars plana vitrectomy: incidence and outcomes. *Retina*. 2008;28:138-142.
- [97] Eifrig CW, Scott IU, Flynn HW, Jr., Smiddy WE, Newton J. Endophthalmitis after pars plana vitrectomy: Incidence, causative organisms, and visual acuity outcomes. *Am J Ophthalmol*. 2004;138:799-802
- [98] Fong CS, Mitchell P, Rochtchina E, Hong T, de Loryn T, Wang JJ. Incidence and progression of epiretinal membranes in eyes after cataract surgery. *Am J Ophthalmol*. 2013 Aug;156(2):312-318.
- [99] Pesin SR, Olk RJ, Grand MG, Boniuk I, Arribas NP, Thomas MA, Williams DF, Burgess D. Vitrectomy for premacular fibroplasia. Prognostic factors, long-term follow-up, and time course of visual improvement. *Ophthalmology*. 1991 Jul;98(7):1109-14.
- [100] Suh MH, Seo JM, Park et al. Associations between macular findings by optical coherence tomography and visual outcomes after epiretinal membrane removal. *Am J Ophthalmol* 2009;147:473-80.
- [101] Inoue M, Morita S, Watanabe et al. Inner segment/outer segment junction assessed by spectral-domain optical coherence tomography in patients with idiopathic epiretinal membrane. *Am J Ophthalmol* 2010;150:834-9.
- [102] Inoue M, Morita S, Watanabe et al. Preoperative inner segment/outer segment junction in spectral-domain optical coherence tomography as a prognostic factor in epiretinal membrane surgery. *Retina* 2011;31:1366-72.
- [103] Kim HJ, Kang JW, Chung H, Kim HC. Correlation of foveal photoreceptor integrity with visual outcome in idiopathic epiretinal membrane. *Curr Eye Res*. 2014 Jun;39(6): 626-33.

